

Soheila Mokmeli MD¹, Mahrokh Daemi MD², Zahra Ayatollahzadeh Shirazi MD¹, Fatemah Ayatollahzadeh Shirazi PhD³, Mitra Hajizadeh MD⁴
Michael Weber, (Deutsche Übersetzungen)

LASER THERAPY ON DIABETIC FOOT ULCER

LASERTHERAPIE BEIM DIABETISCHEN FUSS SYNDROM

Originaltitel des im Journal of Lasers in Medical Sciences Volume 1 Number 1
Autumn 2010 erstpublizierten wissenschaftlichen Arbeit:
Evaluating the Efficiency of Low Level Laser Therapy (LLLT) in Combination
with Intravenous Laser Therapy (IVL) on Diabetic Foot Ulcer, Added to
Conventional Therapy

Summary

Introduction: Low level laser therapy (LLLT) is gaining acceptance in clinical applications. For example, it is used as therapeutic modality in the repair of diabetic foot ulcer when conventional therapy was not effective, separately. The aim of this study is to determine the effect of local and intravenous LLLT for the healing of diabetic foot ulcer.

Material & Methods: This study contains 74 diabetic foot-ulcers which were prone to resistance to conventional therapy. Different stages of diabetic foot are included in this study. The wounds irradiation are performed by the combination therapy of 650 nm and 860 nm laser, with the total energy density of 3.6 J/cm² plus intravenous laser therapy (IVL) with 2.5 MW, 650 nm laser used for 30 minutes. All wounds have been photographed from equal distance, before and after treatments, and all the wounds were staged by a surgeon who was disinterested and neutral about the effects of the laser therapy. Her judgments were based on the visual assessments of the wounds. All the mathematical and statistical analysis is based on the descriptive statistics which, is done by the SPSS 16.

Results: in the result of this study; 62.2% (Forty-six out of the 74 ulcers) completely healed, 12.2% (Nine in numbers) healed more than 50%, 8.1 % (Six in num-

Zusammenfassung

Einleitung: Low-Level-Lasertherapie (LLLT) gewinnt an Akzeptanz in der klinischen Anwendung. Zum Beispiel wird es als therapeutische Modalität bei der Behandlung des diabetischen Fußulkus angewendet, wenn eine konventionelle Therapie nicht wirksam war. Das Ziel dieser Studie war es, die Wirkung der lokalen und intravenösen LLLT für die Heilung des diabetischen Fußsyndroms zu evaluieren.

Material & Methoden: Diese Studie umfasst 74 Patienten mit diabetischen Fuß-Geschwüren, die gegenüber herkömmlichen Therapien resistent waren. Verschiedene Stadien des diabetischen Fußes wurden in dieser Studie untersucht. Die Wund-Bestrahlung erfolgte durch die Kombinationstherapie von 650 nm und 860 nm-Laser mit der Gesamt Energiedichte von 3,6 J/cm² plus intravenöser Laser-Therapie (IVL) mit 2,5 mW, 650 nm für 30 Minuten. Alle Wunden wurden aus dem gleichen Abstand vor und nach der Behandlung fotografiert und von einer Chirurgin, die der Lasertherapie neutral gegenüber stand, beurteilt. Ihre Urteile basieren auf visuellen Einschätzungen der Wunden. Alle mathematischen und statistischen Analysen basieren auf den deskriptiven Statistiken, die durch die SPSS 16 durchgeführt werden.

bers) healed less than 50%, 5.4% (Four in numbers) not healed, 12.2% (Nine in numbers) did not continue their treatment (less than 5 sessions of Laser therapy). Excluding, the wounds in stage 5, more than 80% of each stage's wound, completely healed more than 50%, with in 2 months duration. In this study, we definitely can express that, all the Patients received some degrees of healing, during their laser receiving treatments.

Conclusion: The combined local and intravenous LLLT promote the tissue repair process of diabetic foot ulcer. In this multi-disciplinary method, we achieved a remarkably shorter average healing time of two months, compared with other reported studies with healing time of three to six months.

Keywords

wound, ulcer, diabetic, foot, laser therapy, LLLT, intravenous laser therapy

Ergebnisse: Das Ergebnis dieser Studie war, dass 62,2% (46 von insgesamt 74 Geschwüren) vollständig geheilt, 12,2% (9 in der Anzahl) mehr als 50% praktisch geheilt, in 8,1% (6 in der Anzahl) weniger als 50% geheilt und in 5,4% (4 in der Anzahl) nicht geheilt wurden. 12,2% (neun in Zahlen) brachen die Behandlung (weniger als 5 Sitzungen der Lasertherapie) ab. Nimmt man die Wunden der Stufe 5 heraus, wurden in den 2 Monaten der Studie mehr als 80% jeder Stufe vollständig oder mehr als 50% geheilt. Mit dieser Studie zeigen wir, dass alle Patienten während der Lasertherapie um einige Stufen gebessert wurden.

Schlussfolgerung: Die kombinierte lokale und intravenöse LLLT fördert den Reparaturprozess von Gewebe beim diabetischen Fußsyndrom. Mit dieser multi-disziplinären Methode erzielten wir eine erheblich kürzere durchschnittliche Heilungszeit von zwei Monaten, im Vergleich zu anderen Studien mit einer durchschnittlichen Heilungszeit von drei bis sechs Monaten.

Schlüsselwörter

Wunde, Ulkus, Diabetes, Fuß, Laser Therapie, LLLT, Intravenöse Lasertherapie

INTRODUCTION

Diabetic foot ulcer has been identified as a significant therapeutic challenge in medical fields since a long period of time. Diabetes disease complicated by neuropathy and circulatory damage is the main cause of lower limb amputation, and accounts for more than half of all foot and leg removals each year world wide. According to the report of American Diabetes Association, 82,000 people lose a foot or leg due to diabetes, annually.

Low level laser therapy (LLLT) is gaining acceptance in clinical applications. For example, it is used as therapeutic modality for the repair of diabetic foot ulcer when conventional therapies are not effective [1–2].

Tissue repair is a dynamic interactive process which involves different parameters like mediators, cells and extracellular matrix. Several reports on the use of laser therapy were submitted describing that the healing process is positively affected when the correct parameters of laser are used. Low level lasers have been introduced as one of the treatment modalities for non-healing wounds and several

indications have been introduced for its use in wound healing processes, particularly in indolent wound resistant to conventional treatments. Low-energy photo-stimulation at certain wavelengths can enhance tissue repair by releasing growth factors from fibroblasts and can facilitate the healing process of diabetic wounds [1].

The molecular and cellular mechanisms of LLLT are as follow:

- 1) Target cells are blood leukocytes, fibroblasts, keratinocytes, endotheliocytes, etc.
- 2) Primary acceptors of radiation are porphyrins, which may cause radicals for secondary free radical reactions

¹ Department of Medical Laser, Milad Hospital, Tehran, Iran

² Department of Surgery, Sina Hospital, Tehran University of Medical Sciences, Tehran, Iran

³ College of Science, Tehran University, Tehran, Iran

⁴ Department of Internal ward, Milad Hospital, Tehran, Iran

- 3) The initiation of the secondary free radical reactions due to lipid peroxidation of cell membranes leads to an increase in ion permeability, including Ca^{2+} . The increase in intracellular Ca^{2+} concentration cause phagocytosis to increase production of reactive oxygen species (ROS)
- 4) ROS in the cytoplasm of some cells induces a free-radical activation of synthesis of proteins; the most significant is the de novo synthesis of inducible Nitric oxide (NO) –synthase (iNOS), super oxide dismutase, and various cytokines. NO has many functions in wound healing [3].

The foot ulcer in diabetic patients, as a pivotal event, especially in its last stages demands urgent and aggressive management. Diabetic foot care in all stages needs multi-disciplinary management to control mechanical, wound, microbiological, vascular, metabolic and educational aspects. Achieving good metabolic control of blood glucose, lipids and blood pressure is important in each stage [4]. Aggressive management of diabetic foot ulceration will reduce the number of feet proceeding to infection and necrosis, and thus reduce the number of major amputations in diabetic patients [4].

We arranged the stages of diabetic wound, into five stages using the Texas Diabetic Wound Classification:

Stage 1: The very superficially involvement of the skin and involvement of epidermis with redness.

Stage 2: The involvement of the full thickness of the skin and minor underlying tissue.

Stage 3: The deepest involvement of the full thickness of the skin, and major soft tissue involvement extending into the muscle or tendon.

Stage 4: Involvement of major soft tissue, muscle or tendon obviously and, or even bone.

Stage 5: presenting the necrotic tissue that can't stage the ulcer may contain complicated osteomyelitis.

MATERIALS & METHODS

This study was carried out after approval of local ethics committee in the laser department of Milad Hospital. The patients with different stages of diabetic foot ulcer referred to this ward during the period of three years after signing appropriate written consent entered this study. LLLT and intravenous laser therapy (IVL) were used for 65 diabetic foot-ulcer patients who resisted to conventional treatment. All of the patients received the required, conventional treatments of diabetic wound care, including dressing, antibiotics, controlling diabetes, cholesterol, and blood pressure along with aggressive drug treatment and wound debride-

ment when needed. Before, after and during the laser therapy's procedure.

In those wounds that conventional therapy was not effective, separately, after passing the treatments deadline, in the case of delayed or none healing wounds, laser therapy added to the protocol. Then the results of the both methods compared together considering as two separate groups. Some patients had 2 or 3 ulcers, which included in ulcer count, which made a total number of 74 diabetic ulcers included in this study.

Varieties of different parameters in his study are as the followings:

- 1) The availability percentage of sex distribution in this study was; 70.27% (Fifty- two in numbers) were male patients and 29.73% (Twenty-two in numbers) females.
- 2) The availability of age distribution was: 25.68% (Nineteen in numbers) of < 50 years old, 24.32% (Eighteen in numbers) of 50–60 years old, 27.03% (Twenty in numbers) of 60–70 years old and 22.97% (Seventeen in numbers) being >70 years old and the mean age was 59.69 Y with St Deviation = 1.46.
- 3) The availability distribution of stages of diabetic wound: it was divided into five stages: (Diagram 1).
The 1st stage – 0.0%. (Not available)
The 2nd stage– 21.6%. (Sixteen in numbers)
The 3rd stage – 35.1%. (Twenty-six in numbers)
The 4th stage – 32.4% (Twenty-four in numbers)
The 5th stage – 10.8%. (Eight in numbers)
The availability of the ulcers in 3rd stage was more than the other stages.
- 4) The result of wound culture with antibiogram and the required antibiotic therapy: Most of the ulcers (79.7%) (Fifty nine in numbers) had positive culture, while 6.8% (Five in numbers) of the ulcers had negative results, yet the remaining (13.5%) (Ten in numbers) had no documented result of their wounds culture in their file. This last group, based on their wound examination, didn't need antibiogram. 85.1% (Sixty-three in numbers) of patients were treated with regards to the result of cultures and examination with a suitable antibiotic regime and the remaining did not need the antibiotics in their treatment's schedule.

The Stages of wound (Diagram 1)

LLLТ was applied using the following protocol:

- 1) Intravenous laser radiation (IVL) with 2.5 mW, 650 nm laser (GAALINP/ SIL85–6, IDFI-Behsaz Company, Iran) in order to radiate the blood stream from the large

veins of upper limb, applied intravenously through venue of catheter for 30 minutes.

- 2) Wound irradiation by a combination of red and infra red laser, with the total energy density of 3.6 J/cm^2 in non contact irradiation technique. The ID of lasers was as follow:

- I. GaAs diode laser (LO7 hand-held probe, Mustang 2000 Russia): $\lambda = 860 \text{ nm}$, radiation mode = pulse, peak power output = 100 W , surface area = 1 cm^2 , time = 30 S/cm^2 , frequency = 3000 Hz (the maximum produced frequency by the laser set), pulse duration = 200 nsec , energy density 1.8 J/cm^2 .

- II. GaAlInP diode laser (K30 hand-held probe, AZOR, Technica, Russia): $\lambda = 650 \text{ nm}$, radiation mode = continues, Power = 30 mW , Surface area = 1 cm^2 , Time = 60 S/cm^2 , Energy density = 1.8 J/cm^2 .

- 3) The area of 1 centimeter from the ulcer margins were irradiated with IR laser using a handheld probe LO7 ($\lambda = 860 \text{ nm}$, radiation mode = pulse, peak power output = 100 W , surface area = 1 cm^2 , time = 60 S , frequency = 3000 Hz , pulse duration = 200 nsec , energy density 3.6 J/cm^2) with irradiation technique of direct contact to cover around the wound.
- 4) Irradiation of lymphatic drainage and vascular vessels of wound area including around of external and internal malleolus, fossa popliteal, and inguinal region with IR laser by hand-held probe LO7 ($\lambda = 860 \text{ nm}$, radiation mode = pulse, peak power output = 100 W , surface area = 1 cm^2 , frequency = 3000 Hz , pulse duration = 200 nsec , energy density 0.3 J/cm^2) using in contact scanning of the area. The scanning time was determined according to the regional size for each wound to receive, 0.3 J/cm^2 in its surface area.

The therapeutic sessions were repeated 3–4 times per week (mean 18.45) for an average of 2 months/on average for 2 months; depending on the patients' situation.

Based on the wound healing response, patients were divided into five categories, 1st) completely healed, 2nd) healed more than 50%, 3rd) healed less than 50%, 4th) not healed, 5th) patients who did not followed the treatment sessions for at least five sessions. All wounds have been photographed from equal distance, before and after treatments, and all the wounds were staged by a surgeon who was disinterested and neutral about the effects of the laser therapy. The judgments were based on the visual assessments of the photos. All the mathematical and statistical analyses were completed using descriptive statistics (SPSS version 16).

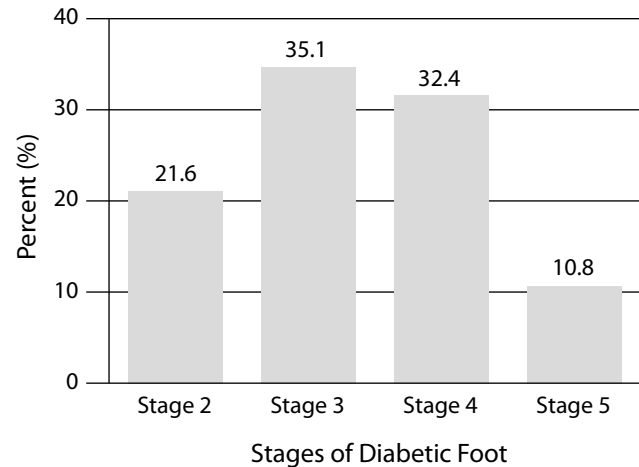


Diagram 1

RESULTS

The total variety response to healing were; 62.2% (Forty-six in numbers) of the ulcers completely healed, 12.2% (Nine in numbers) healed more than 50%, 8.1% (Six in number) healed less than 50%, 5.4% (four in numbers) were not healed, 12.2% (Nine in numbers) did not continue the treatment. In this study, if we omit those patients who did not complete the therapeutic sessions (at least 5 sessions), we can say almost all the patients achieved some degree of healing, and 74.4% of patients got more than 50% to complete healing. The followings are the healing durations and the percentages of healing in each stage of the diabetic wounds:

Stage 2: 86.8% of diabetic wounds in this stage completely healed during 2 months

Stage3: 61.5% of diabetic wounds in this stage completely healed while 7.7% showed more than 50% healing during 2 months.

Stage 4: 58.3% of diabetic wounds in this stage completely healed while 25% showed more than 50% healing during 2 months.

Stage 5: 33.3%, of diabetic wounds in this stage completely healed and 25% showed more than 50% healing within 2–4 months.

The total response to healing (Diagram 2)

DISCUSSION

Diabetic foot problem due primarily to neuropathy and microcirculatory damage imposes considerable morbidity and costs on individuals and societies [5–8].

Diabetic foot care in all stages needs multidisciplinary management to control mechanical, wound, microbiological, vascular, metabolic and educational aspects. Achieving good metabolic control of blood glucose, lipids and blood pres-

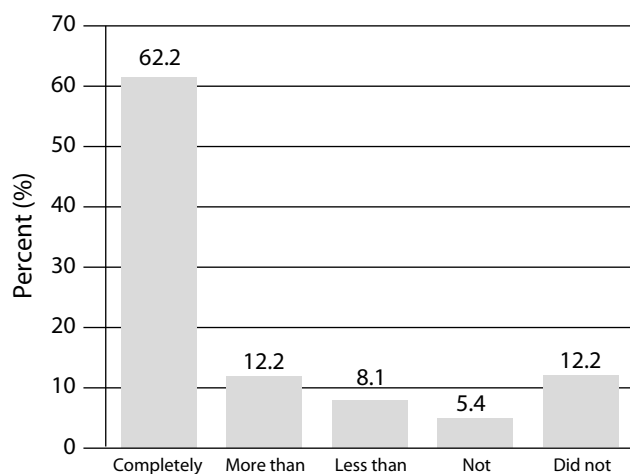


Diagram 2

sure is important in each stage, as is education to teach proper foot care appropriate for each stage [4].

Schindl et al. reported the first case of diabetic foot patient treated with low-intensity laser therapy in 1992 and proposed that this therapeutic method might constitute a useful side effect-free alternative treatment modality for the induction of wound healing of neuropathic ulcers in diabetic patients [9].

Byrnes KR et al. during a study showed that LLLT at an energy density of 4 J/cm² was effective in improving the healing of full-thickness skin wounds (stage III) in an animal model of type II diabetes; and the quantitative analysis of basic fibroblast growth factor expression at 36 h postinjury revealed a threefold increase in the diabetic and non-diabetic Sand Rats after LLLT [10].

LLLT was used concurrently with topical hyperbaric oxygen in an Israeli study of 100 consecutive diabetic foot ulcer patients who had not responded to prior therapies. 81 percent of them were healed in an average of three months (According to the March 2001 issue of Yale Journal of Biology and Medicine) [11].

Landau reported the treatment of 50 patients with chronic diabetic foot ulcers were treated with topical hyperbaric oxygen alone or in combination with LLLT and 42 patients showed complete healing [12].

Low-level laser irradiation has been reported to enhance ATPase activity, long-term erythrocytes membrane proteins as well as lipid bilayer structural changes, and resulting change in membrane ion pumps activities [13], respiratory burst of neutrophils through activation of protein tyrosine kinases and phospholipase C [14]. Also, improvement of skin circulation in patients with diabetic microangio-

pathy has been reported [15]. In addition, according to some clinical researches, laser stimulation at certain wavelengths can also enhance tissue repair by releasing growth factors from fibroblasts and can facilitate the healing process of diabetic wounds [16].

Moreover, low-level laser irradiation has been shown to accelerate collateral circulation, enhance microcirculation [16] as well as relaxation of vascular smooth muscle [16]. LLLT can improve nerve activity and it is reported to be used in the cases of Sacral and trochanteric pressure sores in patients with plegias successfully. Foot ulcerations in patients with diabetic neuropathy are similar, because these wounds occur in tissues that do not have normal innervations. While it is recognized that insensitive tissue increases the likelihood of ulceration outbreak and recurrence [18]. Intravenous laser therapy (IVL) or photohaemotherapy is a method of low level laser therapy that was pioneered in Russia and refers to blood irradiation through an intravenous needle or transcutaneously, venous radiation. The most common used wavelengths include 890 nm, 630 nm, 650 nm, and recently 450 nm. According to the Russian studies IVL increases oxygen content and reduces the partial pressure of carbon dioxide. It eliminates tissue hypoxia, stimulates oxygenation, normalizes tissue metabolism, and activates the nonspecific mechanisms of anti-infectious immunity.

IVL reduces content of C-reactive protein, raises activity of complement, increases the plasma level of immunoglobulins (IgA, IgM, IgG), decreases thrombocyte aggregation ability, and activates fibrinolysis which enhances peripheral circulation [19].

Lebed'kov EV et al. found that IVL has impact on the blood lipid and phospholipid components as well as membrane erythrocyte in patients with diabetes mellitus and pyo-necrotic injuries of lower extremities. Additionally, the results prove that the IVL favorably affects the blood components in a complex treatment of diabetes mellitus [20]. Dr. P. Ramadawon used IVL in combination with LLLT and acupuncture laser therapy to control blood sugar in diabetes [21].

Our work was a multi-method low intensity laser therapy which obtained a very satisfying result comparatively as previously shown through other therapeutic methods. It contained both intravenously and locally low level laser irradiations.

According to the Wagner categories, median healing time increased from 51 (2 M) days in class 1 to 174 (9 M) days in class 4 [22]. In this method we have achieved a very ac-

ceptable goal in order to treat diabetic ulcers, even in highly damaged tissues, in a shorter time (on average of 2 months) as compare to the other reported study [the combination of LLLT and topical hyperbaric oxygen that achieved healing in an average of 3 months) conducted by Landau Z, 2001[11], and it seems that IVL and LLLT together can reduce the treatment time with satisfying healing.

CONCLUSION

In conclusion; the combined local and intravenously LLLT promote the tissue repair process of diabetic foot ulcer. In this multi disciplinary method we obtained a remarkably shorter mean healing time of two months, compared with other reported studies of three to six months. [Excluding the exceptional cases seen; in stage 5, which more than 80% of the diabetic wounds achieved more than 50% of complete healing during 2 months and more after 2 months (for a total period of 4 months), The remaining reached to 58% of complete healing. Means 37% of the cases did not prone any response to healing and the remaining left the therapy before 5th session].

We hope to open a new angel of vision for our medical members in order to reduce the rate of limb amputation, and the number of patients who may suffer, in addition, we hope to make a way for achieving more reasonable treatments in diabetic foot patients, in a very close future.

ACKNOWLEDGEMENT

We would like to appreciate our colleagues: Dr Zahrai, Dr. T. Niko Khorsand and Dr. N. Kazemi. khou for their help and assistance in the study. ■

References

- [1] Maiya GA, Kumar P, Rao L. Effect of low intensity helium-neon (He-Ne) laser irradiation on diabetic wound healing dynamics. J. Photomed Laser Surg 2005 Apr; 23 (2): 187–90.
- [2] Walker MD, Rumpf S, Baxter GD, Hirst DG, Lowe AS. Effect of low-intensity laser irradiation (660 nm) on a radiation-impaired wound -healing model in murine skin. J Laser Surg Med 2000; 26 (1): 41–47.
- [3] Vladimirov IuA, et al. Mar-Apr. (2004): Molecular and cellular mechanisms of the low intensity laser radiation effect. J. Biofizika; 49 (2): 339–50.
- [4] Edmonds M. Diabetic Foot Ulcers: Practical Treatment Recommendations. Drugs 2006; 66 (7): 913–929.
- [5] Saar WE, Lee TH, Berlet GC. The economic burden of diabetic foot and ankle disorders. Foot Ankle Int 2005; 26 (1): 27–31.

ACHTUNG:

Hier muss der
Dummy durch
eine Anzeige
ersetzt werden !!

Bum-Anzeige

- [6] Singh N, Armstrong DG, Lipsky BA. Preventing foot ulcers in patients with diabetes. *JAMA* 2005; 293 (2): 217–28.
- [7] Ramachandran A. Specific problems of the diabetic foot in developing countries. *Diab Metab Res Rev* 1996; 20 (Suppl 1): 19–22.
- [9] The Diabetes Control, Complications Trial Research Group. Lifetime benefits and costs of intensive therapy as practiced in the Diabetes control and complications Trial. *JAMA* 1996; 276: 1409–15.
- [9] Schindl A, Schindl M, Pernerstorfer-Schon H, Kersch K, Knobler R, Schindl L. Diabetic neuropathic foot ulcer: successful treatment by low-intensity laser therapy. *Dermatology* 1999; 198 (3): 314–16.
- [10] Byrnes KR, Barna L, Chenault VM et al. Photobiomodulation improves cutaneous wound healing in an animal model of type II diabetes. *Photomed Laser Surg* 2004 Aug; 22 (4): 281–90.
- [11] Lathram P. Healing Light–Laser Technology Now Making Strides in Wound Care. *Diabetes health magazine*. [Internet]. 2001 Nov. Available from: <http://www.diabeteshealth.com/read/2001/11/01/3427/healing-light/?section=512>
- [12] Landau Z. Topical hyperbaric oxygen and low energy laser for the treatment of diabetic foot ulcer. *Arch. Orthop Trauma Surg* 1998; 117 (3): 156–58.
- [13] Kujawa J, Zavodnik L, Zavodnik I, Buko V, Lapshyna A, Bryszewska M. Effect of low intensity (3.75–2.5 J/cm²) near-infrared (810 nm) laser radiation on red blood cell ATPase activities and membrane structure. *J Clin Laser Med Surg* 2004; 22 (2): 111–17.
- [14] Duan R, Liu TC, Li Y, Guo H, Yao LB. Signal transduction path ways involved in low intensity He–Ne laser induced respiratory burst in bovine neutrophils: A potential mechanism of low intensity laser biostimulation. *Lasers Surg Med* 2001; 29 (2): 174–8.
- [15] Schindl A, Schindl M, Schon H, Knobler R, Havelec L, Schindl L. Low-intensity laser irradiation improves skin circulation in patients with diabetic microangiopathy. *Diab Care* 1998; 21 (4): 580–4.
- [16] Ihsan FR. Low-level laser therapy accelerates collateral circulation and enhances microcirculation. *Photomed Laser Surg* 2005; 23 (3): 289–94.
- [17] Gal D, Chokshi SK, Mosseri M, Clarke RH, Isner JM. (1992) Percutaneous delivery of low-level laser energy reverses histamine-induced spasm in atherosclerotic Yucatan microswine. *Circulation* 1992 Feb; 85 (2): 756–68.
- [18] AR Barker, GD Rosson, AL Dellon. Wound healing in denervated tissue. *Ann Plast Surg* 2006; 57 (3): 339–342.
- [19] Brill GE, Gasparyan LV, Makela AM. Modification in relationships in the system endothelial cell– blood platelet by low level laser radiation. Paper presented at Laser Florence meeting; 2003; Florence, Italy.
- [20] Lebed'kov EV, Tolstykh PI, Marchenko LE, Turkina TI, Krivikhin VT. The effect of the laser irradiation of the blood on its lipid and phospholipid components in diabetes mellitus. *Voen Med Zh.* 1998 Oct; 319 (10): 37–8, 95.
- [21] Ramdawon P: Bioresonance information laser therapy of diabetes mellitus: a first clinical experience of the hypoglycemic effect of low level laser therapy and its perspectives. Paper presented at North American Laser Therapy Association Conference; 1999 Oct; Rockville, Washington D.C., USA.
- [22] Van Acker K, De Block C, Abrams P, Bouten A, De Leeuw I, Droste J et al. The choice of diabetic foot ulcer classification in relation to the final outcome. *Wounds* 2002; 14: 16–25.



Soheila Mokmeli

*Project Manager, Research Unit (COL-Center), Canadian Optic & Laser Production Ltd
Victoria, BC, Canada*

Tel. +1 250 480 7868, E-Mail: dr.mokmeli@yahoo.com

www.laser-consult.ir, www.col-center.ca